

CASE REPORT

Management of a Woman Diagnosed With Trochanteric Bursitis with the Use of a Protonics® Neuromuscular System

Kyndall L. Boyle, MS, PT, OCS,¹
Shane Jansa, MS, PT, CSGS,²
Chad Lauseng, MS, PT,³
Cynthia Lewis, PhD, PT⁴

ABSTRACT

Introduction: Trochanteric bursitis is a common, painful condition affecting the hip. The condition is more prevalent in women than men. Symptoms often include an aching or burning pain in the region of the greater trochanter of the femur that may radiate distally down the extremity or proximally into the lumbar spine. The literature describes medical and physical therapy management of this condition that focuses on local symptoms including: medication, injections, surgery, moist heat, ultrasound, massage, stretching, and orthotics.

Purpose: The purpose of this case report is to describe a woman diagnosed with trochanteric bursitis who received physical therapy management over 3 visits that focused on establishing a neutral pelvic position via unilateral hamstring recruitment using a Protonics® Neuromuscular System. All signs and symptoms of trochanteric bursitis reported on the initial visit were abolished over the course of her physical therapy.

Conclusion: Attention to pelvic position using the Protonics® resulted in successful outcomes for this woman with trochanteric bursitis.

Key Words: *Trochanteric bursitis, Protonics® Neuromuscular System, pelvic asymmetry, women's health, hip pain*

INTRODUCTION

Trochanteric bursitis is a painful condition of the lateral thigh involving compression of the trochanteric bursa, which can lead to marked functional limitations and disability.¹ It affects more women than men and constitutes 60% of hip pain seen in outpatient orthopedic settings.² The trochanteric bursa helps to reduce the inherently high degree of friction and pressure where the fascial plane of the gluteus medius (GM) tendon, iliotibial band (ITB), and tensor fascia lata (TFL) meet the lateral aspect of the greater trochanter.² When the hip is in neutral, the ITB is posterior to the greater trochanter. When the hip is flexed, the ITB is anterior to the greater trochanter.³

The bursa is often irritated by friction from a shortened ITB, via its attachment to the GM as it slides back and forth over the lateral thigh

during gait.⁴ Another cause is thought to be from excessive pelvic displacement from the horizontal plane, which could be from a leg length discrepancy, a Trendelenburg gait caused by weakness of the gluteus medius muscle, and/or running on an irregular or banked surface.⁴ Persons with femoral anteversion⁴ or generalized joint laxity⁵ may be at risk.^{6,7} This condition is common among runners, cross-country skiers, and ballet dancers. Reid suggests that these activities require repetitive hip work and a high volume of single leg stance activities.⁵

The condition is almost always insidious but can be sudden if associated with macrotrauma. Common symptoms include a burning or deep aching pain over or just posterior to the greater trochanter⁸ and may radiate distally along the lateral thigh to knee and/or lower leg or proximally to the lumbar region and mimic a L5 spinal lesion.⁹ Walking, stair ambulation, lying on the affected side, and standing for a long time are often painful. Pain is generally better with rest.⁹

Examination may include: gait observation, hip range of motion measurement, palpation, muscle length testing, muscle strength testing,¹⁰ radiographs, and/or magnetic resonance imaging (MRI) for differential diagnosis for avascular necrosis, fracture, or loose bodies.¹¹ Common physical therapy interventions include modalities: moist heat,¹¹ ultrasound¹¹ stretching of the iliotibial band,¹⁵ and tensor fascia lata (TFL)¹⁰ orthotics, a heel lift, patient education regarding activity modification and correction of training errors such as running surface.¹¹

Common medical interventions include nonsteroidal anti-inflammatory drugs,^{1,2,5} local injections with anesthetic and hydrocortisone,² and in rare cases surgery consisting of bursa resection or longitudinal ITB release.^{1,5,12,13} Modalities may only have short-term relief, and prolonged use of nonsteroidal drugs may have side effects. Short-term response rates following one or more corticosteroid injections range from 60% to 100%, but up to 36% of patients have a relapse within 10 months.^{4,14}

Currently, no explanations or theories are reported in the literature that explains why the ITB and/or TFL become 'tight,' or why

¹DPT, Elon, NC

²Crossroads Physical Therapy,
Lincoln, NE

³Physical Therapy Solutions,
Sioux Falls, SD

trochanteric bursitis is more common in females. However the literature does report that women have more generalized joint laxity (GJL) than men,¹⁵⁻²² and GJL has been a finding in women with trochanteric bursitis.⁵ Women typically have a wider pelvis than men. Perhaps the mechanics of the TFL, GM, and ITB are altered in women because of the width of the pelvis or because of an asymmetrical pelvic position.

PURPOSE

The purpose of this case report is to describe an approach to management of trochanteric bursitis that did not include any local modalities or stretching exercises for 'tight' hip musculature, but focused instead on restoring a pelvic neutral position via unilateral hamstring activation with a Protonics Neuromuscular System. The theory behind this approach to the case was that the trochanteric bursa was irritated and compressed by the ITB because of the asymmetrical pelvic position and restoring a position of symmetry would abolish the symptoms.

CASE DESCRIPTION

Examination-History

A 36-year-old woman who worked as an office manager was referred by her primary care physician to an outpatient orthopedic physical therapy practice. She had a diagnosis of left

trochanteric bursitis and secondary low back pain. She complained of a 2-year history of insidious left lateral leg and buttock pain, which she rated as a 4 to an 8 on a 10 point scale (0=no pain, 10=worst possible pain).

A functional index score using the Therapeutic Associates Outcome System (TAOS) was a 17 out of 45 placing her in the category of 'very limited function.' The TAOS assesses function on a variety of measures including walking, work, personal care, sleeping, recreation, and other tasks depending on the region of involvement.²³ Functional limitations included: pain when sitting for greater than 20 minutes, standing for greater than 5 minutes, and a reduction in the number of hours worked. Rest in a supine position alleviated the pain.

Past medical history was unremarkable. The patient was taking a prescription of Vicodin, and had no prior physical therapy. Her goals were to stand and walk as much as she desired without pain and return to full-time work.

Examination-Tests and Measures

Standing observation revealed the patient's weight shifted to the right lower extremity, and her left foot placed anterior to the right foot. This position, in combination with the weight shift resulted in relative hip adduction on the

right and abduction on the left. Visual observation of posture revealed an excessive lumbar lordosis and thoracic kyphosis, and her right shoulder girdle was lower than the left. Range of Motion: Passive hip range of motion was measured with a goniometer in sitting, the standard position for measurement.²⁴ Passive ROM measurements for the left hip were 33° internal rotation with a tissue stretch end feel, 20° external rotation with a firm end feel, and right hip were 33° internal rotation with a tissue stretch end feel, 25° external rotation with a firm end feel. Moderate tenderness to palpation of the left greater trochanter region, gluteus medius, and buttock were reported. Special tests included (1) the sidelying femoral acetabular joint (FAJ) adduction test (Ober's Test), (2) the supine FAJ extension test (Modified Thomas Test), and (3) the Lower Trunk Rotation (LTR) test were used to assess pelvic-femoral position (Figures 1-6).^{25,26} The LTR is a generalized test of spinal mobility. One is testing for symmetry of spinal rotation as well as range of motion. Results were: positive Ober's tests bilaterally (left greater than right), positive left Modified Thomas test, and a positive left LTR test (Table 1). The left leg was noted as shorter than the right in supine visualizing the medial malleoli; however, no measurements were taken.



Figure 1. Sidelying Femoral Acetabular Joint (FAJ) Adduction (Ober Test) - positive



Figure 2. Sidelying Femoral Acetabular Joint (FAJ) Adduction (Ober Test) - negative




Figure 3. Supine FAJ Extension (Modified Thomas Test) - Positive




Figure 4. Sidelying Femoral Acetabular Joint (FAJ) Adduction (Ober Test) - negative



Figure 5. Supine Lower Trunk Rotation (LTR) Test - positive




Figure 6. Supine Lower Trunk Rotation (LTR) Test - negative

Table 1. Physical Therapy Outcomes for a Female Patient Diagnosed with Trochanteric Bursitis

Examination Test or Measure	Initial Visit Start of session	Initial Visit End of session	Second Visit	Third Visit (1 year follow-up)
Ober's	(+) Bilateral, (L>R)	(-) Bilateral	(-) Bilateral	(-) Bilateral
Modified Thomas	(+) L	(-) L	(-) Bilateral	(-) Bilateral
Lower Trunk Rotation (LTR)	(+) L	(-) L	(-) Bilateral	(-) Bilateral
Therapeutic Associates Outcome System (TAOS)	17/45	Not assessed	45/45	45/45
Pain rating	4-8/10	2/10	0/10	0/10

EVALUATION

The positive left Ober's, Modified Thomas, and LTR tests are thought to suggest an anteriorly tilted, forwardly rotated, left innominate and a left femur that moved with it into passive internal rotation.^{26,27} This position would create relative left hip flexion, altering the TEL/TB position more anteriorly increasing the compressive forces over the trochanteric bursa. Also it is theorized that the innominate position was associated with the functional leg length discrepancy, ie, short leg on the left side. These biomechanical changes associated with her asymmetrical pelvic position were hypothesized as the cause of her symptoms. Therefore the focus of this case was to correct faulty mechanics throughout the kinetic chain by correcting the pelvic asymmetry to a neutral position. Goals included the abolishment of pain (0/10) and the complete return of function (45/45 Taos score).

INTERVENTION

A Protonics neuromuscular system was placed on her left leg (Figure 7) because of the positive tests on the left side indicating pathomechanics of the left innominate.²⁶ The system is placed with an axis of motion at the knee joint and with the distal struts approximately 1 inch

proximal to the malleoli and the proximal struts approximately 3 inches from the pubic symphysis. Protonics was also an ideal choice of intervention because the patient's schedule would not permit her to return more than once for follow-up.

The device was developed in 1998, has 4 US patents, and is distributed by OrthoRehab Inc. in Tempe, Arizona. Protonics is a system that applies resistance that is independent of speed or gravity to the hamstring musculature during knee flexion to assist in posteriorly rotating the pelvis,^{26,28} and in bringing the femur into a more neutral position in the frontal plane.²⁹ A high level of resistance is used during hamstring curls to achieve symmetrical pelvic position and a low level of resistance is used while walking/during ADLs to maintain the pelvic position.

While research using the Protonics System for trochanteric bursitis has not been reported previously, researchers have reported the effectiveness of the system in decreasing anterior knee pain. Two studies have reported measures of: hamstring and quadriceps strength (isokinetic equipment); EMG activity of vastus lateralis and vastus medialis oblique (VL/VMO); patellofemoral congruence angle (radiograph), function (Kujala questionnaire), and pain (VAS).^{29,30}

Schneider et al³⁰ compared 2 therapeutic approaches for the treatment of persistent patellofemoral pain syndrome. Forty subjects, with ages ranging from 16 to 40 years were divided into 2 groups. Twenty received 8 weeks of physical therapy consisting of proprioceptive neuromuscular facilitation (PNF) exercises in an outpatient setting for a 1-hour session, twice a week. Twenty used the Protonics System on the involved leg for hamstring curls done in 5 positions for 15 minutes, 3 times a day. Subjects who used the Protonics System demonstrated decreased pain, increased strength of the vastus

medialis, and a reduction in the patellofemoral congruence angle (PFC). No significant changes in pain, strength, or PFC were observed in the group receiving the PNF therapeutic program.

Timm²⁹ reported a study of 100 subjects having patellofemoral syndrome. Fifty subjects received treatment using the Protonics System for 4 weeks. Fifty subjects received no treatment for 4 weeks and served as controls. The 50 subjects who used the system wore the device 'as much as possible' throughout the day during activities of daily living on a setting of low resistance. At the end of 4 weeks, the control group had no change in symptoms while the treatment group had improvement in patellofemoral congruence and over all function, and a reduction in patellofemoral pain.

From these 2 studies, the Protonics System appears to be beneficial in managing patients with patellofemoral syndrome via repositioning of the pelvis and femur. Pelvic and femur repositioning may have application for individuals having trochanteric bursitis.

During the first clinical visit, the patient performed 15 hamstring curls in prone, supine, seated, and standing positions with the system set at a resistance level of '7', (on a scale from 1-9) as described in the Protonics Repositioning Protocol.²⁶ Care was taken to ensure the patient maintained a neutral hip and spine position during the exercises, eg, using a pillow under her thigh to keep the knee and hip in the same parallel plane during prone, supine, and sitting positions; and a pillow under her abdomen during prone exercises. Immediately after she performed the initial set of exercises in the clinic using the Protonics system, the special tests were repeated. All 3 special tests were negative.

The patient was instructed to do 15 repetitions of the hamstring curls with the system on her left side in the 4 positions 3 times a day as a home exercise program. This program was done

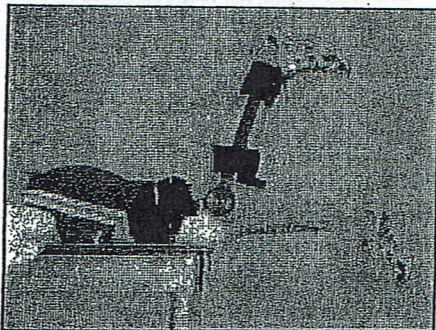


Figure 7. Protonics® Neuromuscular System- used for a prone hamstring curl for pelvic repositioning.

to maintain her pelvis and femur in a neutral position. She also was instructed to wear the system on a resistance level of a '2' for 1 to 2 hours during activities of daily living, 3 times a day for a total of 6 hours per day. At 6 weeks the patient was instructed to gradually decrease the use of Protonics to 1 time per day, to every other day, to 2 to 3 times per week, and then use it on an as needed basis.

OUTCOMES

Within the same visit, (on visit one), the patient's Ober and modified Thomas went from positive to negative, and her pain rating went from a 4/10 to a 2/10 (Table 1). Via phone, 3 days later she reported she was completely pain free (0/10) and had discontinued taking her medication. On visit 2 (6 weeks later), the patient reported a very high adherence to her program, and her Ober's, Modified Thomas, and IIR tests were still negative, and no leg length discrepancy was noted. Her functional index score, using the TAOS was a 45, placing her in the category of 'active function' (Table 1). She reported being able to sit for greater than 1 hour and walk for greater than 1 mile without pain.

On her third visit (1 year later), her Ober, Modified Thomas, and IIR tests remained negative, her pain rating remained at a 0/10, no leg length discrepancy was noted, and her TAOS score remained a 45 (Table 1). She was able to stand and walk pain-free for as long as she desired. She reported she had not used the Protonics for the past 2 months, but had been using it about once a month since her 6-week visit, when she had some activity-related soreness.

DISCUSSION

This case report illustrates unique management for trochanteric bursitis that does not include local modalities or stretching. Rather than targeting the local symptoms directly and the apparently 'tight' soft tissue of the hip directly, the physical therapist targeted the pathomechanics theorized to be responsible for the tissue irritation of the left pelvis resulting in local symptoms, thereby targeting the local symptoms indirectly. The diagnosis of trochanteric bursitis for this case does seem fitting since there was local pain and tenderness over the bursa, and the diagnosis of 'secondary low back pain' may have been given because of the pain located into the buttock, as the trochanteric bursa does not refer pain.

The Ober's test was positive on the patient's initial examination. Traditionally this finding would lead to a clinical reasoning of 'tight' ITB and intervention consisting of ITB stretching. However, in this particular case, the treating therapist did not limit the Ober's test to just muscle contracture, but instead considered the impact of

a left forward pelvis on passive hip adduction during an Ober's test (or EAJ Adduction test). This apparent inability to adduct may be explained by a bony block of the femur on the condyloid rim of the acetabulum and/or an increase in hip musculature tone because of the forwardly rotated and anteriorly tilted left pelvis. After aggressive recruitment of her left hamstrings via Protonics resistance, her Ober's was negative in less than 30 minutes.

The patient's Modified Thomas test was positive on her initial examination. This finding typically leads to a clinical reasoning of 'tight' hip flexors and intervention consisting of hip flexor stretching. Again the physical therapist did not limit this observation to 'tight' hip flexors but to an asymmetrical pelvic position, and the modified Thomas test was interpreted as 'increased neuromuscular tension' of the hip flexors because of pelvic alignment rather than 'decreased flexibility.' The positive left IIR test suggested a lumbar-sacral orientation to the right, therefore her legs rotated more easily to the right than the left. These findings are also consistent with a left anteriorly tilted innominate. If the patient's Ober's and IIR tests were negative, ie, neutral pelvic alignment, the therapist would have interpreted the positive Thomas as an indication for stretching the hip flexors.

The anteriorly tilted and forwardly rotated left innominate leads to passive internal femoral rotation.³¹⁻³⁵ As a result, her hip internal rotators (ITL, anterior gluteus medius, gluteus minimus) would be in a shortened position, and her femoral external rotators (piriformis, obturator internus and externus, superior and inferior gemelli, quadratus femoris and gluteus maximus) would be lengthened, and at a mechanical disadvantage.³⁶ The over lengthened musculature would appear 'tight' because the sarcomeres were stretched apart and had little range to further lengthen. An anteriorly tilted and forwardly rotated innominate is also theorized to be associated with a functional or apparent leg length discrepancy. The leg may be short on the side of the forward rotation and anterior tilt, assuming the hip capsule and ligaments (iliofemoral and pubofemoral) are stable and have good integrity or a functionally long leg may be seen if the hip capsule and ligaments are unstable and have poor integrity causing the femoral head to be seated more inferiorly in the acetabulum.³⁶ Another cause of the femoral head being seated more inferiorly may be the poor recruitment of the ischiocondylar portion of the adductor magnus, which the authors theorize may be responsible for seating the femoral head superiorly (compressing it up into the acetabulum).

The Protonics Neuromuscular System was used on her left leg to achieve a neutral pelvic and sacral position by activating the hamstring and anterior pelvic rotation^{23,28,36} and reciprocal inhibition of the hip flexors.³⁶ The hamstrings attach to the ischium and indirectly to the sacrum via the sacrotuberous ligament, so contraction of the hamstring can result in movement of the pelvis and sacrum. The resistance to the hamstrings by the Protonics Neuromuscular System can be applied during daily activities in both open kinetic chain and closed kinetic chain positions. This program ensures that the patient receives neuromuscular input during functional activities. The resistance is consistent regardless of the speed of the movement, regardless of the patient's position (prone, sitting, supine, standing, or walking).

During the hamstring curls, the hip and spine of the patient are kept in a neutral position to assure the neuromuscular system is retraining muscles at their optimal length-tension relationship. Performing the hamstring curls in the prone position first, followed by supine, sitting, and then standing progressively challenges the patient's neuromuscular system.²⁶ The hamstring curls with Protonics resistance appeared to successfully reposition her pelvis (from an anteriorly tilted and forwardly rotated position) to neutral as evidenced by the negative Ober's, Modified Thomas, and IIR tests. The PROM of hip internal and external rotation was not remeasured.

The frequency of the home repositioning program (15 HS curls at a level 7 in 4 positions) and retraining program (3 times/day for 1-2 hours during daily activities, ie, 3-6 hours total) is thought to re-educate and reinforce maintenance of a neutral pelvic and femoral position by hamstring activation. Consequently, the excessive demands on her hip musculature were removed and symptoms resolved. The patient was able to reposition her pelvis (negative tests at the end of her initial examination) and maintain carry-over as demonstrated by negative special tests, TAOS scores indicating normal function, and a pain scale of 0 at the second (6 weeks) and third visits (1 year later).

This approach to management of trochanteric bursitis had positive outcomes by targeting what was thought to be the underlying pathomechanics resulting in chronic bursitis, associated symptoms, and functional limitations. Interventions focused on pelvic repositioning using contraction of the hamstrings, which resulted in abolishment of her pain and functional limitations. She did not require injections, medications, orthotics, stretching, and any other modalities or follow-up care. More research is

needed to provide evidence for the association between pelvic asymmetry and trochanteric bursitis, pelvic asymmetry and leg length discrepancy, and pelvic asymmetry and other musculoskeletal dysfunctions commonly seen in women such as low back pain, pelvic floor dysfunction, stress incontinence, and sacroiliac dysfunction.

REFERENCES

1. Slawski DP, Howard RE. Need title. *Am J Sports Med.* 1997;25(1):86-89.
2. Anderson BC, Muirhead G. Need title. *Patient Care.* 2000;36(5):196.
3. American Academy Orthopedic Surgeons. On Line Service Fact Sheet Snapping Hip. Available at <http://orthoinfo.aaos.org/fact/>. Accessed June 1, 2001.
4. Malone TR, McPoil T, Nitz A. *Orthopedic and Sports Physical Therapy.* 3rd ed. St. Louis, Mo: Mosby; 1997:497-499.
5. Reid DC. *Sports Injury Assessment and Rehabilitation.* New York, NY: Churchill Livingstone Inc.; 1992.
6. Foldes K, Balint P, Gaal M, Buchanan WW, Balint GP. Nocturnal pain correlates with effusions in diseased hips. *J Rheumatol.* 1992; 19(11):1756-1758.
7. Fox JM. Injuries to the pelvis and hip in athletes: anatomy and function. In: Nicholas JA, Hershman EB, eds. *The Lower Extremity and Spine in Sports Medicine.* St. Louis, Mo: Mosby; 1986.
8. Donatelli R, Wooden MJ. *Orthopaedic Physical Therapy.* New York, NY: Churchill Livingstone; 1994:518.
9. Little H. Trochanteric bursitis: A common cause of pelvic girdle pain. *Can Med Assoc J.* 1979;120:456-458.
10. Magee D. *Orthopedic Physical Assessment.* 3rd ed. Philadelphia Pa: WB Saunders Company; 1997.
11. Jones DL, Ethard RE. Diagnosis of trochanteric bursitis versus femoral neck stress fracture. *Phys Ther.* 1977;77(1):58-67.
12. Hartley A. *Practical Joint Assessment: A Sports Medicine Manual.* St. Louis, Mo: Mosby Year Book; 1976:571.
13. Zltan DJ, Clancy WG, Keene JS. A new operative approach to snapping hip and refractory trochanteric bursitis in athletes. *Am J Sports Med.* 1986;14:201.
14. Ege Rasmussen KJ, Fano N. Trochanteric bursitis. Treatment by corticosteroid injection. *Scan J Rheumatol.* 1985;14:417-420.
15. Beighton P, Grahame R, Bird H. *Hypermobility of Joints.* Berlin. Springer-Verlag; 1983: 136-149.
16. Biro F, Gewanter HL, Baum J. The hypermobility syndrome. *Pediatrics.* 1983;72(5): 701-706.
17. Calguneri M, Bird HA, Wright V. Changes in joint laxity occurring during pregnancy. *Annals Rheum Dis.* 1982;41(2):126-128.
18. Gedalia A, Person DA, Brewer EJ, Giannini EH. Hypermobility of the joints in juvenile episodic arthritis/arthralgia. *J Pediatrics.* 1985;107(6):873-876.
19. Larsson L, Baum J, Mudholkar GS. Hypermobility: Features and differential incidence between the sexes. *Arthritis Rheum.* 1987; 30(12):1426-1430.
20. Howes RG, Isdale IC. The loose back: an unrecognized syndrome. *Rheum Phys Med.* 1971;11(2):72-77.
21. Kessler RM, Herling D. *Management of Common Musculoskeletal Disorders Physical Therapy Principles and Methods.* Philadelphia, Pa: Harper & Row Publishers Inc.; 1983:10-17.
22. Klemp P, Stevens JE, Isaacs S. A hypermobility study in ballet dancers. *J Rheumatol.* 1984;11(5):692-696.
23. Schunk D. TAOS Functional index: Orthopaedic rehabilitation outcomes tool. *J Rehabil Outcomes Meas.* 1998;2(2):55-61.
24. Norkin C, White J. *Measurement of Joint Motion A Guide to Goniometry.* Philadelphia, Pa: FA Davis Company; 1995:132-135.
25. Kendall FP, McCreary EK, Provance PG. *Muscles Testing and Function.* 4th ed. Williams and Wilkins; 1993:210-363.
26. Hruska RJ. Influence of the Pelvic-Femoral Complex on Anterior Knee Pain. Lincoln, Neb: Postural Restoration Institute; 2001: 20.
27. Boyle K. *Examination Screening for Lumbar-Sacral-Pelvic-Femoral Complex Asymmetry* [poster presentation]. Greensboro, NC: NCPTA Fall Conference; September 2001.
28. Antoun N, Kerns K, Kramer A, et al. The Influence of the Protonics Knee Brace on Pelvic Position. Research Reports 2000. Loma Linda, Calif: Loma Linda University School of Allied Health Professions; 2000:21-36.
29. Timm KE. Randomized controlled trial of Protonics on patellar pain, position, and function. *Med Sci Sports Exercise.* 1998; 30(5):665-670.
30. Schneider F, Labs K, Wagoner S. Chronic patellofemoral pain syndrome: Alternatives for cases of therapy resistance. *Knee Surg Sports Traumatol Athrosc.* 2001;9(5):290-295.
31. Cailliet R. *Knee Pain and Disability.* Philadelphia, Pa: FA Davis Co; 1973:140-142.
32. Kendall F, McCreary E, Geise P. *Muscle Testing and Function.* 4th ed. Baltimore, Md: The Williams and Wilkins Co; 1993:216-217.
33. Norkin C, Levangie P. *Joint Structure and Function.* 2nd ed. Philadelphia, Pa: FA Davis Co.; 1992:366-368.
34. Platzer W. *Locomotor System.* 4th ed. New York, NY: Thieme Medical Published Inc.; 1992:192.
35. Polley H. *Physical Examination of the Joints.* 2nd ed. Philadelphia, Pa: WB Saunders Co.; 1978:98.
36. Hruska R. Myokinematic Restoration-An Integrated Approach to Treatment of Lower-Half Musculoskeletal Dysfunction course notes. Lincoln, Neb: Postural Restoration Institute; December 2001.

progressive THERAPEUTICS

Time Saving Educational Materials
Women's Health Program Development

- ♦ Everything You Need to Start Adult and Pediatric Incontinence Programs
- ♦ Orthopedic Pelvic Floor Exercises for Pelvic Girdle Stability
- ♦ Pocket Size Weekly Urinary Logs

Save Money and Hours of Work!

Private education/training available for
Pelvic Floor and SI Dysfunctions

For more info visit our website at
www.progressivetherapeutics.com

Or call (888) 340-1500